

The Five Most Common Pathomechanical Foot Types (Rearfoot varus, forefoot varus, equinus, plantarflexed first ray, forefoot valgus)

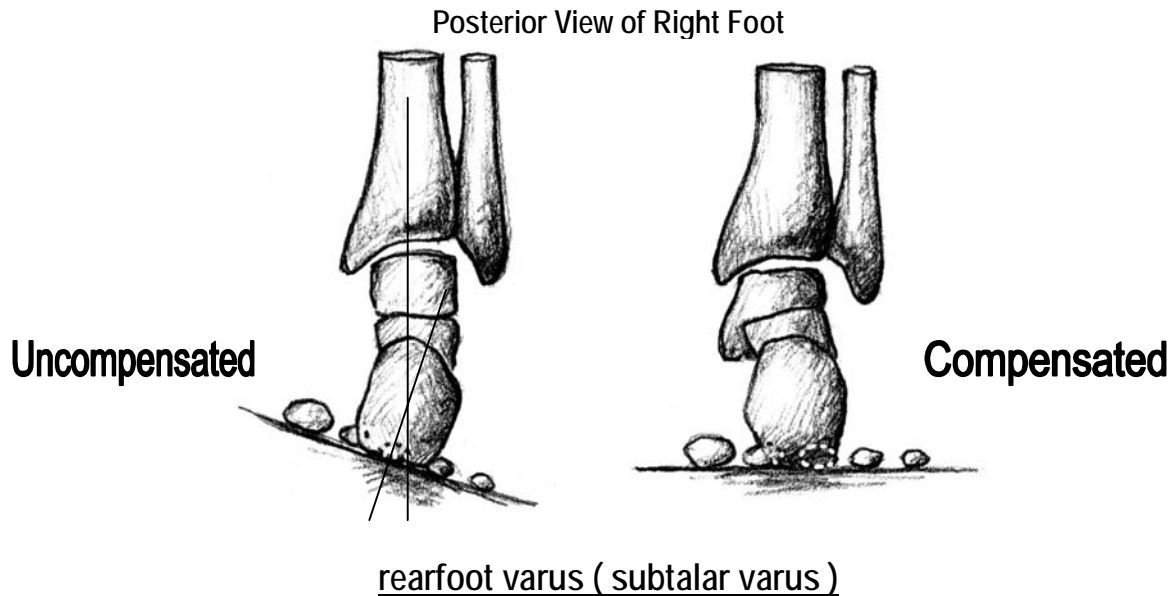
Pathomechanical foot types usually refer to structural deformities that cause the foot to compensate upon weight-bearing. When the foot is non weight-bearing and off the ground, a structural deformity is not an issue. However, because we rely so heavily on the proper functioning of our feet in everyday life, we need to accommodate structural problems so that we can move forward in locomotion with comfort. The foot needs to adjust to varying terrain and accept the body's weight from above. If there is a structural problem (meaning fixed in a specific position) the foot must compensate in order to move the body forward in locomotion. Below, we have outlined the five most common structural deformities.

Note: Compensated - refers to a change in the structural alignment or position of one part of the foot to neutralize the effect of a structural problem in another part of the foot.

Uncompensated – refers to the structural position of the whole foot or one part of the foot in a non weight-bearing situation.

Rearfoot Varus

This is a positional deformity where the entire foot is inverted relative to the ground when the subtalar joint is in its neutral position, as shown below.



This is by far the most common foot disorder we will see. Exists in about 85% of the patient population that has pronation problems.

This is the positional deformity demonstrated as inversion of the rearfoot relative to the ground upon weight-bearing in the posterior view. Non weight-bearing, uncompensated posterior view will show a varus angle between the midline of the lower 1/3 of the leg and the bisection of the calcaneus (refer to diagram). This deformity does not appear in a plaster slipper cast because the cast will only show the relationship between the forefoot and the rearfoot. The problem is not intrinsic to the foot. The problem is the inverted foot relative to the leg.

Three types of rearfoot varus are clinically seen.

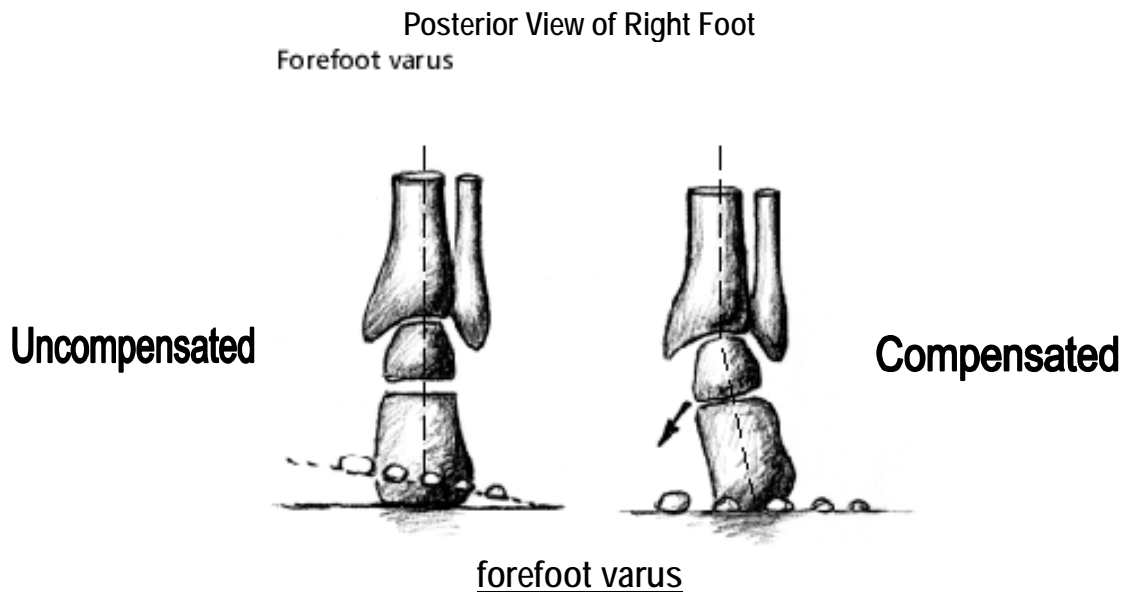
1. **uncompensated.** - The heel functions in an inverted position. The degree of tibial varum (bow leg) is greater than the amount of available calcaneal eversion through subtalar joint pronation.
2. **partially compensated** - The heel functions inverted, but to a lesser angle than the total deformity. The degree of tibial varum is only slightly greater than the available calcaneal eversion.
3. **compensated** - The heel assumes a vertical position to the ground. Tibial varum is equal to the amount of available subtalar pronation.

Clinical observations and symptoms:

Plantar callus mets. 2,3,4; Heel spur syndrome; Tailor's bunion; leg fatigue; knee pain and low back pain

Forefoot Varus

A constant structural inversion of the forefoot with respect to a bisection of the posterior of the calcaneus when the subtalar joint is in neutral position, as seen below in the Uncompensated view as shown.



This is an inverted position of the forefoot relative to the rearfoot at the level of the midtarsal joint. It is due to inadequate frontal plane torsion occurring during normal development of the foot. Upon weight-bearing, calcaneal eversion is required to fully compensate this deformity. Ten to fifteen percent of patients treated with biomechanical problems have forefoot varus. This disorder causes some of the most severe pronation problems and foot deformities.

The three variations of forefoot varus seen are:

1. **uncompensated** - The rearfoot is rigid and cannot compensate. Instead of subtalar joint compensation, it will have to try to take place in the midtarsal joint.
2. **partially compensated** - In this case the degree of forefoot varus is greater than the available degree of calcaneal eversion.
3. **compensated** - When the degree of forefoot varus is equal to or less than the degree of calcaneal eversion.

Forefoot supinatus - Long term compensatory calcaneal eversion can eventually twist the forefoot into a soft tissue or positional varus position of the forefoot relative to the rearfoot. This is not an osseous abnormality. It mimics forefoot varus. It will disappear with the use of foot orthotics.

Clinical observations and symptoms:

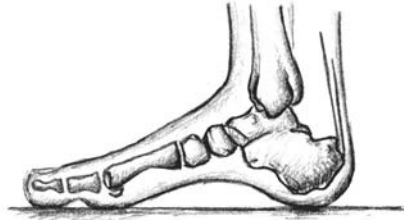Intractable Plantar Keratoma's 1,2,4; callus 1 and hallux; plantar fasciitis; neuroma; hallux abducto valgus; posterior tibial tendonitis; low back pain

Equinus

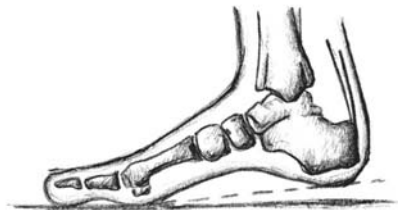With the subtalar joint in neutral position, an equinus foot has less than 10 degrees of ankle dorsiflexion.

Medial View of Right Foot

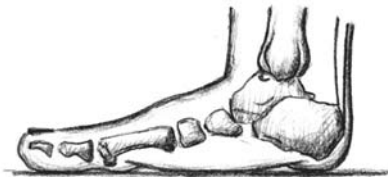Normal, neutral foot



Neutral Foot
with Tibial
progression, normal
10°, normal heel lift



Compensated
forefoot caused by
Equinus at the ankle.



This deformity occurs when an inadequate amount of ankle joint dorsiflexion is present. When this exists, compensation occurs with subtalar joint pronation, which subsequently unlocks the midtarsal joint, collapsing in the midfoot. The foot then cannot function normally in propulsion. With locomotion and the momentum of the leg lifting the heel, the midfoot collapses causing a 'rocker bottom' type effect. In any case, something's got to give, in order for the leg, hips and pelvis to continue forward in locomotion.

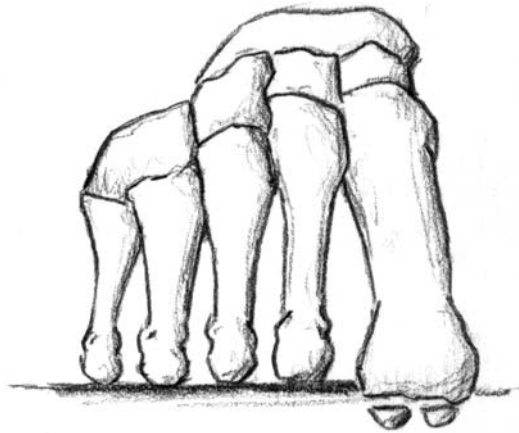
Clinical observations and symptoms:

Severe hallux subluxation; bouncing gait; plantar callus 2,3,4; dorsal corns on toes; hammer toes; leg fatigue; talo-navicular pain; severe postural symptoms

Flexible Plantarflexed 1st Ray

A displacement of the 1st metatarsal bone below the level of the other metatarsal bones.

Anterior View of Right Foot



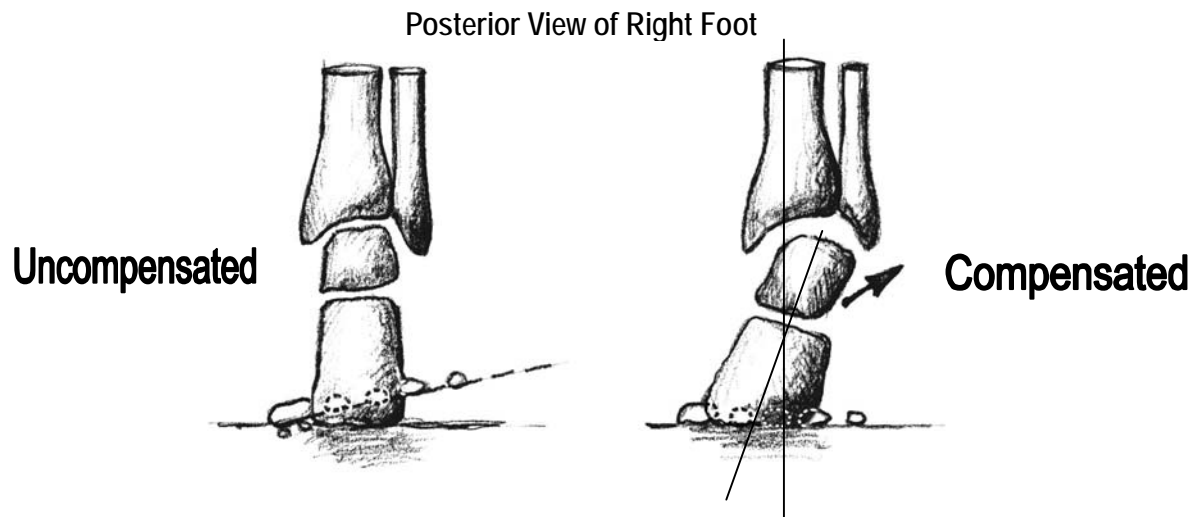
A first metatarsal bone is one whose neutral position is below the level of the lesser metatarsals, but can be moved back to or above that level by some force applied to its plantar aspect. Off weight-bearing examination produces the appearance of forefoot valgus. This type of foot functions like a subtalar varus or forefoot varus type deformity as the compensation takes place by dorsiflexing the 1st ray with subtalar joint pronation.

Clinical observations and symptoms

Dorso-medial bunion; hammer toes, HD 5th toe; leg fatigue; low back pain; plantar fasciitis; lateral knee pain.

Forefoot Valgus

A constant structural eversion of the forefoot. This is a structural or positional deformity that is most common in the **forefoot**.



This is an everted position of the forefoot relative to the rearfoot at the level of the midtarsal joint. Inversion of the lateral column of the foot must occur to allow the forefoot to propel the supporting surface during the midstance and propulsive phases of gait.

The two forms of forefoot valgus are:

1. **flexible forefoot valgus** - There is sufficient flexibility in the midtarsal joint to allow the lateral column of the foot to reach the supportive surface during the stance phase of gait. The heel may function perpendicularly, but the amount of compensation that occurs leads to an unstable gait with late pronation through midstance into propulsion.
2. **rigid forefoot valgus** - When the range of motion in the midtarsal joint is not enough to allow the lateral column of the foot to touch the ground, rearfoot supination/compensation is required. This is rarely seen clinically.

Clinical observations and symptoms:

Lateral heel callus; Intractable Plantar Keratoma 1,5; Sesamoiditis; hammer toes; plantar fasciitis; lateral ankle pain

Rearfoot Valgus

This is an extremely rare biomechanical presentation. It is associated with severe tibial valgum (knock knees) and excessive subtalar pronation.